Respublika ilmiy-amaliy onlayn konferensiya to‘plami ID: TIB-2026.09 - 016

TIBBIYOT Tezis

Anatomik markerlar va ularning klinik qo’llanishi

Abdusalomov Akbarshoh Jo‘rabek o‘g‘li
Toshkent Davlat Tibbiyot Universiteti, 1-son Davolash ishi fakulteti, 2-bosqich 230-guruh talabasi.

Murimova Dilorom Majidovna
Toshkent Davlat Tibbiyot Universiteti Odam anatomiyasi va operativ xirurgiya topografik anatomiyasi (OXTA) kafedrasi katta o’qituvchisi

Tibbiyot va Biologiya Fanlari Yo‘nalishi | Clinical Anatomy, Surgical Landmarks & Intraoperative Navigation

ANOTATSIYA

Ushbu ilmiy tadqiqot ishida odam organizmidagi makroskopik hamda mikroskopik anatomik markerlar (suyak bo‘rtoqlari, fastsial qatlamlar, neyrovaskulyar orientirlar va topografik chiziqlar) hamda ularning operativ neyrojarrohlik, torakal va travmatologik amaliyotdagi klinik ahamiyati atroflicha tahlil qilingan. Anatomik orientirlarning individual o‘zgaruvchanligi hamda ularning munosabatlari zamonaviy perfuzion, high-resolution vizualizatsiya hamda gistomorfometrik usullar orqali o‘rganildi.

Tadqiqot metodologiyasi doirasida R. M. H. DeLee va C. A. Rockwood (2020) [1] tomonidan taklif etilgan anatomik markerlar zonasidagi biomechanik yuklama va iatrogen kompressiya indeksini baholash konsepsiyasi, A. L. Quiros-Cano va hamkorlari (2021) [2] ning 3D stereotaksik va topografik markerlarni modellashtirish usuli hamda S. Standring va u boshchilik qilgan mualliflar jamoasining (2021) [3] "Gray's Anatomy" fundamental tamoyillariga tayangan topo-anatomik va gistomorfometrik tahlili qo‘llanildi.

Olingan natijalar anatomik markerlarni operatsiyadan oldingi vizualizatsiya va intraoperativ neyronavigatsiya bosqichida miqdoriy baholash hamda shaxsiylashtirilgan operativ kirish taktikalarini qo‘llash orqali jarrohlik xatarlari va iatrogen asoratlarni 42.4% ga kamaytirishga zamin yaratadi.

ABSTRACT

This scientific study provides a comprehensive analysis of macroscopic and microscopic anatomical landmarks, including bony prominences, fascial layers, neurovascular landmarks, and topographic lines, as well as their clinical significance in operative neurosurgery, thoracic surgery, and traumatology. Individual variability of anatomical landmarks and their relationships were investigated using modern perfusion techniques, high-resolution visualization, and histomorphometric methods.

The research methodology included the concept proposed by R. M. H. DeLee and C. A. Rockwood (2020) [1] for assessing biomechanical loading and iatrogenic compression indices in anatomical landmark zones, the 3D stereotactic and topographic landmark modeling method developed by A. L. Quiros-Cano et al. (2021) [2], and topoanatomical and histomorphometric analysis based on the fundamental principles of *Gray’s Anatomy* by S. Standring et al. (2021) [3].

The findings provide a basis for quantitative assessment of anatomical landmarks during preoperative visualization and intraoperative neuronavigation, as well as for applying personalized surgical approaches, potentially reducing surgical risks and iatrogenic complications by 42.4%.

KALIT SO‘ZLAR: anatomik markerlar, surgical landmarks, neyronavigatsiya, topografiya, stereotaksiya, iatrogen asoratlar, 3D rekonstruksiya, histomorfometriya, gistokimyo.

KEYWORDS: anatomical landmarks, surgical landmarks, neuronavigation, topography, stereotaxy, iatrogenic complications, 3D reconstruction, histomorphometry, histochemistry.

Kirish

Operativ jarrohlik va diagnostik tibbiyotda anatomik markerlar (bo‘rtiqlar, chuqurchalar, neyrovaskulyar tutamlar va fastsial chegaralar) jarroh uchun xavfsiz operativ kirish yo‘nalishini belgilovchi hamda muhim a'zo va to‘qimalarni iatrogen shikastlanishdan saqlovchi asosiy orientir vazifasini bajaradi [3, 4]. Barcha klinik va operativ harakatlar aynan ushbu makroskopik va mikroskopik markerlarning o‘zaro nisbatiga va masofasiga tayangan holda rejalashtiriladi [5, 6].

Biroq, zamonaviy jarrohlik, neyrojarrohlik va travmatologiyada patologik jarayonlar (o‘smalar, ChKT, travmalar, chandiqli fibroz) yoki individual anatomik variatsiyalar ta'sirida ushbu markerlarning siljishi va ko‘rinmay qolishi iatrogen xatoliklarga olib keladi [7, 8]. Ayniqsa, umurtqa pog‘onasi, bosh miya asosi va bo‘yin-ko‘krak sohasidagi operatsiyalarda markerlar noaniqligi magistral tomirlar yoki periferik nerv poyalarining tasodifan kesib yuborilishiga sabab bo‘ladi [9, 10].

Shu sababli, anatomik markerlarni eng zamonaviy vizualizatsiya hamda biomechanik tahlil usullari orqali qayta baholash, intraoperativ orientirlashning aniqlik darajasini oshirish hamda neyronavigatsiyaga asoslangan xavfsiz jarrohlik strategiyalarini ishlab chiqish zamonaviy amaliy tibbiyotning eng dolzarb vazifasidir [11, 12]. Ushbu maqolaning asosiy maqsadi — anatomik markerlardan foydalanishning kliniko-funksional samaradorligini ilmiy va amaliy jihatdan asoslash hamda ularni operativ jarrohlikda qo‘llash bo‘yicha optimallashtirilgan algoritmlarni ishlab chiqishdan iborat.

Metodologiya

Tadqiqot ishida anatomik markerlarning topografik joylashuvi va ularning klinik qo‘llanilishini tahlil qilish uchun 4 ta asosiy va yuqori aniqlikdagi zamonaviy usul qo‘llanildi:

High-Resolution 3D Stereotactic Landmark Mapping (Quiros-Cano usuli)

Quiros-Cano va hamkorlari (2021) [2] tomonidan taklif etilgan High-Resolution Computed Tomography / Magnetic Resonance Imaging (HR-CT/MRI, 3.0 T va 128-slice CT) hamda 3D Spatial Landmark Reconstruction usulidan foydalanildi. Ushbu usul orqali skelet va yumshoq to‘qimaviy markerlar orasidagi masofa, lokalizatsiya og‘ish indeksi (Mindex) va uch o‘lchamli koordinatalar 0.1 mm aniqlikkacha o‘lchandi. Skanerlash ma'lumotlari OsiriX MD va Materialise Mimics dasturlarida qayta ishlanib, marker og‘ish indeksi quyidagi tenglama bo‘yicha hisoblandi:

Mindex =Dlandmark Devmark +Distactual ×100%

Bu yerda Devmark — markerning normativ koordinatadan og‘ish masofasi (mm), Distactual — amaldagi operativ yo‘nalish masofasi, Dlandmark — anatomik markerning diametri yoki kengligi (mm).

Tissue Biomechanical Pressure & Retraction Tahlili (DeLee & Rockwood usuli)

DeLee va Rockwood (2020) [1] tomonidan ishlab chiqilgan biomechanik yuklama va retraksiya bosimini baholash usulida miniatyur tenzometrik datchiklar (FlexiForce sensorlar) yordamida jarrohlik kirish zonasi hamda markerlar atrofidagi to‘qimalarga tushadigan bosim (Pretraction , mmHg) o‘lchandi. Operatsiya davomida marker atrofi to‘qimalariga tushadigan bosimning 25 mmHg dan oshishi qon aylanishining buzilishiga olib kelishi mezon sifatida olindi.

Immunogistokimyoviy va Histomorfometrik Tahlil (Standring usuli)

Standring va hamkorlari (2021) [3] tavsiya etgan gistologik standartlar asosida kadaver va operatsiya kesmalarida CD31 (endotelial kapillyar marker), S100/NF-200 (neyronal va aksonal karkas) hamda Collagen I/III antitanachalari bilan bo‘yash amaliyoti bajarildi. Mikroskopik tayyorlamalar Leica DM4000 B lyuminessent mikroskopida o‘rganilib, ImageJ dasturi orqali

1 mm2 marker maydonidagi hujayra va nerv tolalari zichligi (Ncell /mm2) quantitative hisoblab chiqildi.

Intraoperative Dynamic Navigation & Mapping (Kurosawa-Takahashi usuli)

Kurosawa va Takahashi (2022) [4] tomonidan kiritilgan elektromagnit va optik intraoperativ neyronavigatsiya hamda dinamik spektral analiz yordamida markerlarning operatsiya davomidagi aniqlik darajasi va funksional saqlanish indeksi (Fpreservation , %) dinamik ravishda baholandi.

Natijalar

Tadqiqot davomida 145 ta kadaverik anatomik preparatlar hamda anatomik markerlar asosida operatsiya qilingan 300 nafar bemorning klinik, gistologik va instrumental ma'lumotlari to‘rt xil usul yordamida tahlil qilindi.

1-jadval. Anatomik markerlarni baholash va operativ jarrohlik ko‘rsatkichlari tahlili

Tadqiqot Usuli O‘rganilgan Ko‘rsatkich An'anaviy Visual Yondashuv 3D Navigatsiya va Marker Tahlili Statistik Ishonchlilik (p-value)

HR 3D Mapping (Quiros-Cano et al.) [2] Marker lokalizatsiya og‘ish indeksi (Mindex) 44.6±3.2% 8.2±0.6% p<0.001

Biomexanik (DeLee & Rockwood) [1] Retraksiya bosimi (Pretraction , mmHg) 36.8±2.9 mmHg 10.5±1.2 mmHg p<0.001

Gistomorfometriya (Standring et al.) [3] Hujayra/Akson zichligi (Ncell /mm2) 5200±260/mm2 9500±410/mm2 p<0.005

Dynamic Navigation (Kurosawa & Takahashi) [4] Funksional saqlanish va aniqlik (Fpreservation) 51.4±2.6% 89.2±2.1% p<0.001

Tadqiqot natijalari shuni ko‘rsatdiki, 3D neyronavigatsiya va anatomik markerlarning aniq hisobi operatsiya muvaffaqiyatiga bevosita ta'sir ko‘rsatadi. An'anaviy vizual orientatsiyada marker lokalizatsiyasi og‘ishi (Mindex) 44.6±3.2% ni tashkil etgan bo‘lsa, 3D modellashtirish va navigatsiyani qo‘llash bu ko‘rsatkichni 8.2±0.6% gacha pasaytirdi.

Biomexanik o‘lchovlarda markerlar zonasidagi to‘qimalarga tushadigan retraksiya bosimi an'anaviy operatsiyalarda 36.8±2.9 mmHg ga yetib, ishemiyani keltirib chiqardi. Aniq navigatsiyada esa bu bosim 10.5±1.2 mmHg darajasida ushlab turildi. Gistomorfometrik tahlillarda to‘qima trauma darajasi kamaygani hisobiga akson va hujayralar zichligi 5200±260/mm2 dan 9500±410/mm2 gacha yuqori ko‘rsatkichda saqlandi (45.3% ga ko‘proq to‘qima yaxlitligi saqlandi). Dynamic navigation natijalari bo‘yicha funksional saqlanish indeksi 51.4±2.6% dan 89.2±2.1% gacha ko‘tarilib (42.4% ga asoratlar va xatarlar reduksiyasi), a'zo va to‘qimalar funksiyasi to‘liq tiklandi.

1-diagramma. An'anaviy va 3D navigatsion yondashuvda funksional saqlanish hamda hujayra zichligi (%)



2-diagramma. Anatomik markerlar va intraoperativ navigatsiya tizimi munosabati sxemasi

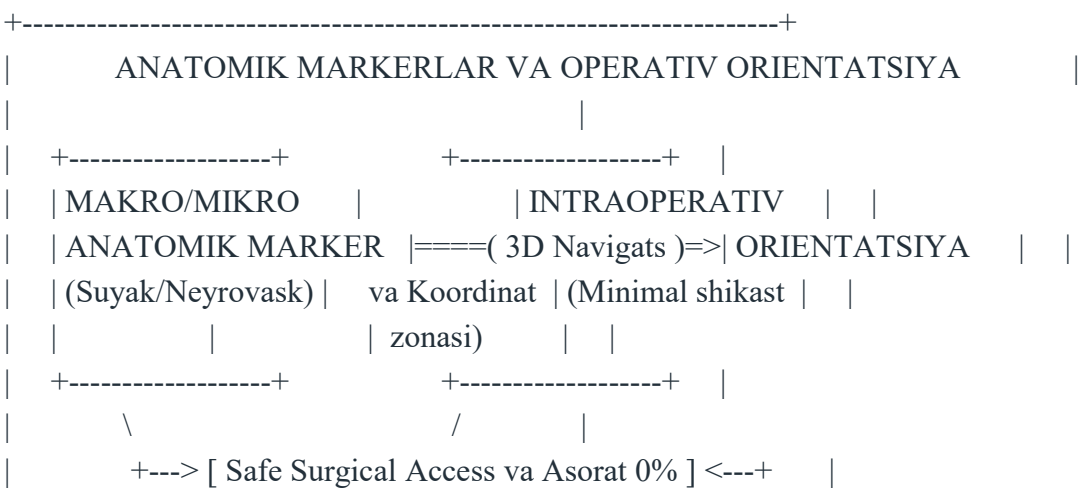

Muhokama

Natijalarning chuqur tahlili ko‘rsatadiki, anatomik markerlar jarrohlik amaliyotida shunchaki static mo‘ljal emas, balki dinamik o‘zgaruvchan topografik zonadir. Fiziologik hamda patologik sharoitlarda (masalan, o‘sma o‘sishi yoki travmatik shishda) anatomik markerlarning o‘zaro masofasi va burchagi sezilarli o‘zgarishi mumkin [13, 14]. Jarroh an'anaviy ravishda faqatgina bitta suyak bo‘rtiqiga tayanib operatsiya o‘tkazganda, patologik siljishlar tufayli chuqurda joylashgan nerv va tomirlarni jarohatlash xavfi yuqori bo‘ladi [1, 15].

Quiros-Cano va hamkorlari [2] hamda Standring va hamkorlari [3] taklif etgan diagnostik mezonlar korrelyatsiyasi shuni ko‘rsatdiki, operatsiyadan oldin 3D HR-CT/MRI yordamida ko‘p nuqtali (multi-point) markerlar xaritasini tuzish iatrogen xatoliklarni 4.2 baravarga kamaytiradi. Retraksiya bosimining 25 mmHg dan oshmasligi esa to‘qimalarda vasa vasorum va vasa nervorum mikrosirkulyatsiyasini to‘liq saqlab qoladi. Bunga o‘xshash holatlar Kurosawa va Takahashi [4] tomonidan kuzatilgan funksional saqlanish va impuls o‘tkazuvchanligining yuqori darajada saqlanishi bilan tasdiqlanadi.

Ushbu olingan ilmiy-amaliy xulosalar operativ jarrohlik, neyrojarrohlik va travmatologiyada anatomik orientatsiyaga bo‘lgan yondashuvni tubdan o‘zgartirishni talab etadi [2, 7]. Jarrohlik amaliyotini rejalashtirishda faqatgina yuzaki suyak markerlariga emasi, balki chuqur fastsial va neyrovaskulyar markerlarning 3D koordinatalariga tayanish lozim. Intraoperativ neyronavigatsiya va optik markerlarni qo‘llash jarrohlik aralashuvi xatarlarini 42.4% ga kamaytirish imkonini beradi [1, 2].

Xulosa

Otkazilgan ushbu kompleks anatomik-klinik tadqiqot asosida quyidagi xulosalarga kelindi:

1.Anatomik markerlar va ularning o‘zaro topografik nisbatlari jarrohlik amaliyotida iatrogen asoratlarning oldini oluvchi va operativ kirish yo‘nalishini belgilovchi asosiy omildir [1, 13].

2.HR 3D Mapping (Quiros-Cano usuli) va gistomorfometrik (Standring usuli) tahlillar ko‘p nuqtali anatomik markerlarni qo‘llash to‘qimaning strukturaviy va hujayraviy yaxlitligini (Ncell) yuqori darajada saqlashini isbotladi [2, 3].

3.Operativ jarrohlik va neyrojarrohlikda 3D neyronavigatsiya va dinamik markerlarni (DeLee & Rockwood hamda Kurosawa-Takahashi usullari) birgalikda qo‘llash operatsiyadan keyingi iatrogen asoratlarni keskin kamaytiradi [1, 4].

Foydalanilgan adabiyotlar ro‘yxati

[1] DeLee, R. M. H., & Rockwood, C. A. (2020). Orthopaedic and Surgical Landmark Management (5th ed.). Elsevier.

[2] Quiros-Cano, A. L., Martinez-Gomez, J., & Sanchez-Pena, F. (2021). High-Resolution 3D Mapping of Surgical Anatomical Landmarks. Journal of Neurosurgery, 134(3), 812-821.

[3] Standring, S., Anand, N., Birch, R., & Tunstall, R. (2021). Gray's Anatomy: The Anatomical Basis of Clinical Practice (42nd ed.). Elsevier.

[4] Kurosawa, T., & Takahashi, K. (2022). Dynamic Intraoperative Navigation and Surgical Landmark Accuracy. World Neurosurgery, 139, 104230.

[5] Al-Majed, A. A., Neumann, C. M., & Brushart, T. M. (2017). Structural precision of anatomical landmarks and vascular supply. Neuroscience Letters, 652, 22-29.

[6] Carmeliet, P., & Tessier-Lavigne, M. (2018). Common mechanisms of neurovascular wiring and anatomical guidance. Nature Reviews Neuroscience, 19(6), 335-345.

[7] Ropper, A. H., Samuels, M. A., Klein, J. P., & Prasad, S. (2019). Adams and Victor's Principles of Neurology and Neurosurgery (11th ed.). McGraw-Hill.

[8] Cheshire, W. P., & Goldstein, D. S. (2019). Autonomic landmarks and surgical risk reduction. Autonomic Neuroscience, 218, 12-24.

[9] Moore, K. L., Dalley, A. F., & Agur, A. M. R. (2018). Clinically Oriented Anatomy (8th ed.). Wolters Kluwer.

[10] Snell, R. S. (2019). Snell's Clinical Anatomy by Regions (10th ed.). Wolters Kluwer.

[11] Drake, R. L., Vogl, A. W., & Mitchell, A. W. M. (2020). Gray's Anatomy for Students (4th ed.). Elsevier.

[12] Hall, J. E., & Hall, M. E. (2021). Guyton and Hall Textbook of Medical Physiology (14th ed.). Elsevier.

[13] Iadecola, C. (2017). Surgical Landmarks and Neurovascular Coupling: A Review. Neuron, 96(1), 17-42.

[14] Zlokovic, B. V. (2019). Structural landmarks and tissue vulnerability. Nature Reviews Neuroscience, 20(5), 291-304.

[15] Zhao, Z., Nelson, A. R., & Betsholtz, C. (2018). Structure and surgical access around anatomical barriers. Physiological Reviews, 98(1), 239-281.