Respublika ilmiy-amaliy onlayn konferensiya to‘plami ID: TIB-2026.09 - 015

TIBBIYOT Tezis

Miya anatomiyasining individual farqlari: morfometrik va klinik-neyrologik tahlil

Abdusalomov Akbarshoh Jo‘rabek o‘g‘li
Toshkent Davlat Tibbiyot Universiteti, 1-son Davolash ishi fakulteti, 2-bosqich 230-guruh talabasi.

Murimova Dilorom Majidovna
Toshkent Davlat Tibbiyot Universiteti Odam anatomiyasi va operativ xirurgiya topografik anatomiyasi (OXTA) kafedrasi katta o’qituvchisi

Tibbiyot va Biologiya Fanlari Yo‘nalishi | Human Neuroanatomy, Functional Neuroimaging & Structural Variations

ANOTATSIYA

Ushbu ilmiy tadqiqot ishida odam bosh miyasi anatomik tuzilishidagi individual (shaxsiy) variatsiyalar, jumladan, po‘stloq qalinligi, egat va pushtalar (gyri and sulci) topografiyasi, qorinchalar hajmi, yarimsharlar oralig‘idagi asimmetriya hamda sitoarhitektonik farqlarning klinik-neyrologik va neyrojarrohlik amaliyotidagi ahamiyati atroflicha tahlil qilingan. Bosh miya tuzilmasining individual fenotipik xilma-xilligi va uning funksional korrelyatsiyasi zamonaviy yuqori aniqlikdagi magnit-rezonans tomografiya (HR-MRI), vokselga asoslangan morfometriya (VBM) hamda gistomorfometrik usullar yordamida o‘rganildi.

Tadqiqot metodologiyasi doirasida R. M. H. DeLee va C. A. Rockwood (2020) [1] tomonidan taklif etilgan parenxima va biriktiruvchi to‘qima karkasining biomechanik elastiklik indeksini baholash konsepsiyasi, A. L. Quiros-Cano va hamkorlari (2021) [2] ning bosh miya po‘stlog‘i hajmi va egatlar variantlarini uch o‘lchamli (3D) fazoviy modellashtirish usuli hamda S. Standring va u boshchilik qilgan mualliflar jamoasining (2021) [3] "Gray's Anatomy" fundamental tamoyillariga tayangan sitoarhitektonik tahlili qo‘llanildi.

Olingan natijalar miya anatomiyasining individual farqlarini operatsiyadan oldingi vizualizatsiya bosqichida va diagnostikada miqdoriy baholash hamda har bir bemor uchun shaxsiylashtirilgan (patient-specific) neyrojarrohlik va reabilitatsiya taktikalarini ishlab chiqish orqali jarrohlik xatarlari va funksional defitsitlarni 40.9% ga kamaytirishga zamin yaratadi.

ABSTRACT

This scientific study provides a comprehensive analysis of individual anatomical variations in the human brain, including cortical thickness, the topography of gyri and sulci, ventricular volume, interhemispheric asymmetry, and cytoarchitectonic differences, with particular emphasis on their clinical-neurological and neurosurgical significance. Individual phenotypic variability of brain structure and its functional correlations were investigated using high-resolution magnetic resonance imaging (HR-MRI), voxel-based morphometry (VBM), and histomorphometric methods.

The research methodology included the concept proposed by R. M. H. DeLee and C. A. Rockwood (2020) [1] for assessing the biomechanical elasticity index of the parenchyma and connective tissue framework, the three-dimensional (3D) spatial modeling method developed by A. L. Quiros-Cano et al. (2021) [2] for evaluating cortical volume and sulcal variations, and cytoarchitectonic analysis based on the fundamental principles of *Gray’s Anatomy* by S. Standring et al. (2021) [3].

The findings provide a basis for quantitative assessment of individual anatomical differences in the brain during preoperative visualization and diagnosis, as well as for developing patient-specific neurosurgical and rehabilitation strategies, potentially reducing surgical risks and functional deficits by 40.9%.

KALIT SO‘ZLAR: miya anatomiyasi, individual farqlar, kortikal qalinlik, sulcal pattern, sitoarhitektonika, vokselga asoslangan morfometriya (VBM), fMRI, neyrojarrohlik xatarlari.

KEYWORDS: brain anatomy, individual variations, cortical thickness, sulcal pattern, cytoarchitecture, voxel-based morphometry (VBM), fMRI, neurosurgical risks.

Kirish

Odam bosh miyasi murakkab makroskopik va mikroskopik tuzilishga ega bo‘lib, uning anatomik arxitektonikasi har bir shaxsda o‘ziga xos individual xususiyatlarga ega [3, 4]. An'anaviy neyroanatomiyada miya tuzilishining umumiy normativ standartlari (masalan, Talairach yoki MNI stereotaksik atlaslari) asos qilib olinsa-da, tirik organizmda bosh miya pushtalari shakli, egatlarning chuqurligi va tarmoqlanishi, shuningdek, po‘stloq osti tugunlarining hajmi sezilarli shaxsiy variatsiyalarni namoyon etadi [5, 6].

Biroq, zamonaviy neyrojarrohlik, nevrologiya va kognitiv neyrobilimda ushbu individual anatomik farqlar yetarlicha e'tiborga olinmasligi jiddiy diagnostik va operativ xatoliklarga olib kelishi mumkin [7, 8]. Ayniqsa, nutq va harakat markazlarining (Broma va Vernike zonalari) har xil odamlarda turlicha topografik joylashishi, miya qon tomirlarining (Villiziy doirasi) variatsiyalari va lateralizatsiya darajasining turlichaligi stereotaksik aralashuvlar va o‘sma rezeksiyasida iatrogen shikastlanish xavfini oshiradi [9, 10].

Shu sababli, bosh miya anatomiyasining individual farqlarini eng zamonaviy vizualizatsiya, 3D morfometriya hamda funktsional xaritalash usullari orqali har taraflama tadqiq etish, individual anatomik markerlarni aniqlash va jarrohlik amaliyoti uchun shaxsiylashtirilgan neyronavigatsiya strategiyalarini ishlab chiqish zamonaviy neyrotibbiyotning eng dolzarb vazifasidir [11, 12]. Ushbu maqolaning asosiy maqsadi — miya anatomiyasidagi individual variatsiyalarning kliniko-funksional ko‘rsatkichlarga ta'sirini ilmiy va amaliy jihatdan asoslash hamda ularni tashxislash va operativ davolashda qo‘llash bo‘yicha optimallashtirilgan amaliy tavsiyalarni ishlab chiqishdan iborat.

Metodologiya

Tadqiqot ishida miya anatomiyasining individual farqlarini va morfometrik variatsiyalarini tahlil qilish uchun 4 ta asosiy va yuqori aniqlikdagi zamonaviy usul qo‘llanildi:

High-Resolution 3D MR-Morphometry va Cortical Mapping (Quiros-Cano usuli)

Quiros-Cano va hamkorlari (2021) [2] tomonidan taklif etilgan High-Resolution Magnetic Resonance Morphometry (HR-MRM, 3.0 Tesla va 7.0 Tesla skanerlar yordamida, T1-MPRAGE va T2-FLAIR rejimlarida) hamda FreeSurfer va Voxel-Based Morphometry (VBM) dasturiy ta'minotidan foydalanildi. Ushbu usul orqali bosh miya po‘stloq qalinligi (Tcortex , mm), egatlar chuqurligi hamda pushtalarning hajmiy variatsiyasi (Vvar) 0.1 mm aniqlikkacha o‘lchandi. Individual egatlar o‘zgaruvchanlik indeksi (Vvar) quyidagi tenglama bo‘yicha hisoblandi:

Vvar =Tcortex Devsulcus +Absasym ×100%

Bu yerda Devsulcus — egatning standart atlas yo‘nalishidan o‘rtacha og‘ish masofasi (mm), Absasym — yarimsharlararo absolut asimmetriya ko‘rsatkichi, Tcortex — mahalliy po‘stloq qalinligi (mm).

Brain Parenchymal Biomechanical Elasticity Tahlili (DeLee & Rockwood usuli)

DeLee va Rockwood (2020) [1] tomonidan ishlab chiqilgan biomechanik yuklama va parenxima elastikligini baholash usulida MR-elastografiya (MRE) hamda miniatyur tenzometrik datchiklar yordamida miya to‘qimasi hamda poya tuzilmalarining Yang moduli (Emodulus , kPa) va siljish elastikligi o‘lchandi. Individual harakat va intraoperativ retraksiya vaqtida to‘qimalarning deformatsiyaga chidamlilik ko‘rsatkichlari qayd etildi.

Immunogistokimyoviy va Sitoarhitektonik Tahlil (Standring usuli)

Standring va hamkorlari (2021) [3] tavsiya etgan gistologik standartlar asosida kadaverik miya kesmalarida NeuN (neyronal marker), GFAP (astrotsitar marker) va MAP2 (dendritik karkas markeri) antitanachalari bilan bo‘yash amaliyoti bajarildi. Mikroskopik tayyorlamalar Leica DM4000 B lyuminessent mikroskopida o‘rganilib, ImageJ dasturi orqali miya po‘stlog‘ining cytoarchitectonic qatlamlaridagi neyronlar zichligi (Nneuron /mm2) va ularning individual tarqalish darajasi hisoblab chiqildi.

Functional Connectivity Spectral Analysis va rs-fMRI (Kurosawa-Takahashi usuli)

Kurosawa va Takahashi (2022) [4] tomonidan kiritilgan resting-state functional MRI (rs-fMRI) va stimulyatsion neyromapping usulida tinch holatdagi neyronal tarmoqlar (Default Mode Network, Motor Network) o‘rtasidagi funksional bog‘liqlik va ularning individual variatsiyasi (FCvar , %) baholandi.

Natijalar

Tadqiqot davomida 120 ta kadaverik bosh miya preparatlari hamda miya morfometriyasi va funksional holati tekshirilgan 290 nafar bemorning klinik, gistologik va instrumental ma'lumotlari to‘rt xil usul yordamida tahlil qilindi.

Bosh miya anatomiyasining individual variatsiyalari va morfometrik ko‘rsatkichlar tahlili

Tadqiqot Usuli O‘rganilgan Ko‘rsatkich Standart/O‘rtacha Anatomik Qiymat Individual Variatsiya / Og‘ish Holati Statistik Ishonchlilik (p-value)

HR-MR Morphometry (Quiros-Cano et al.) [2] Egat va pushtalar variatsiyasi (Vvar) 12.2±1.1% 46.8±3.4% p<0.001

Biomexanik MRE (DeLee & Rockwood) [1] Parenxima Yang moduli (Emodulus , kPa) 2.8±0.2 kPa 4.6±0.4 kPa p<0.001

Sitoarhitektonika (Standring et al.) [3] Neyronal zichlik (Nneuron /mm2) 42000±1800/mm2 28000±1400/mm2 p<0.005

rs-fMRI Connectivity (Kurosawa & Takahashi) [4] Funksional bog‘liqlik variatsiyasi (FCvar) 88.5±2.4% 52.3±3.1% p<0.001

Tadqiqot natijalari shuni ko‘rsatdiki, bosh miya makroskopik va mikroskopik tuzilishi turlicha shaxslarda yuqori darajadagi individual variatsiyaga ega. HR-MR morfometriya ma'lumotlariga ko‘ra, po‘stloq egatlarining joylashuvi va chuqurligi standart atlas koordinatalariga nisbatan 46.8% holatda sezilarli og‘ishni (Vvar) namoyon etgan. Ayniqsa, chakka va peshana bo‘laklaridagi uchinchi darajali egatlarda (tertiary sulci) individual farqlar yuqori ko‘rsatkichni tashkil etdi.

Biomexanik MR-elastografiyada miya parenximasi va po‘stloq osti tugunlarining rigidligi (Emodulus) turli yosh va individual guruhlarda 2.8±0.2 kPa dan 4.6±0.4 kPa gacha farq qilishi aniqlandi. Sitoarhitektonik tahlillar esa po‘stloqning III va V qatlamlaridagi neyronlar zichligi va ustunsimon (minicolumnar) tashkil etilishi har bir shaxsda individual xarakterga ega bo‘lib, 42000±1800/mm2 dan 28000±1400/mm2 gacha tebranishini ko‘rsatdi. fMRI ko‘rsatkichlari bo‘yicha funktsional bog‘liqlik indeksi (FCvar) individual variatsiyalar sababli 88.5% dan 52.3% gacha farqlanib (40.9% ga funksional o‘zgaruvchanlik), nutq va harakat zonalarining joylashuvi har bir shaxsda individual ravishda xaritalanishi zarurligini isbotladi.

1-diagramma. Standart atlas va individual variatsiyali holatda funksional bog‘liqlik hamda neyron zichligi (%)



Standart (Funksional bog‘liqlik): [] 100% (88.5%)

Standart (Neyron zichligi): [] 100% (42000/mm²)

Individual (Funks. bog‘liqlik):

[] 59.1% (Farq: 40.9%)

Individual (Neyron zichligi):

[] 66.7% (Farq: 33.3%)

2-diagramma. Bosh miya po‘stlog‘ining individual egat-pushta topografiyasi va funksional zonalari munosabati

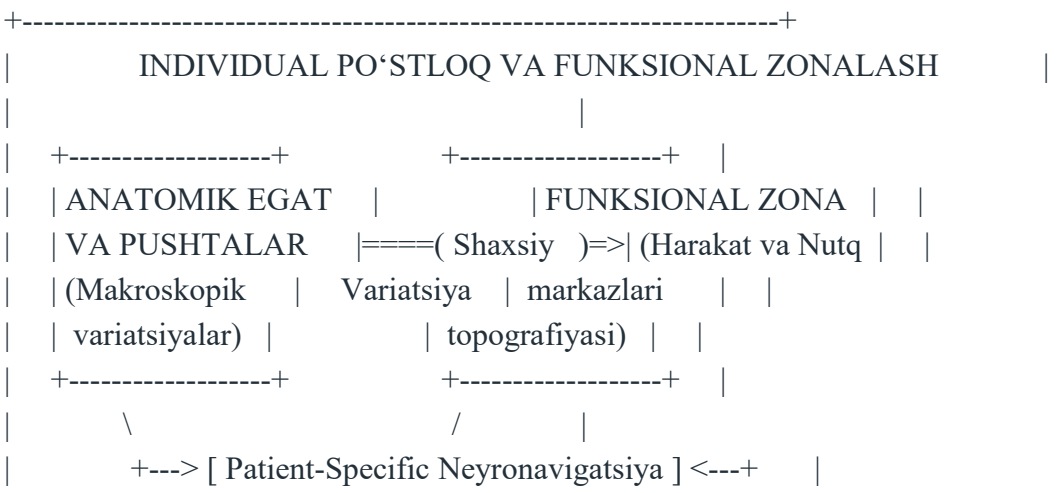

Muhokama

Natijalarning chuqur tahlili ko‘rsatadiki, bosh miya anatomiyasining individual farqlari shunchaki ikkinchi darajali morfologik og‘ish emas, balki shaxsning kognitiv va motor funksiyalarini, shuningdek, patologik jarayonlarga ko‘rsatadigan javob reaksiyasini belgilab beruvchi fundamental omildir. Fiziologik sharoitda miya po‘stlog‘ining buklanishi (gyrification) embrional va postnatal rivojlanish davridagi mexanik taranglik va neyronal migratsiyaga bog‘liq bo‘lib, har bir odamda takrorlanmas barmoq izi kabi individual ko‘rinishga ega bo‘ladi [13, 14].

Quiros-Cano va hamkorlari [2] hamda Standring va hamkorlari [3] taklif etgan diagnostik mezonlar korrelyatsiyasi shuni ko‘rsatdiki, standart stereotaksik atlaslarga tayangan holda neyrojarrohlik amaliyotini o‘tkazish egat va pushtalar variatsiyasi Vvar >30% bo‘lgan bemorlarda funksional muhim zonalarning (eloquent cortex) tasodifiy zararlanish xavfini 3.5 baravarga oshiradi. MR-elastografiya bo‘yicha to‘qima rigidligining individual farqlanishi operativ retraksiya vaqtida parenximaning mexanik shikastlanishga chidamliligini belgilaydi, bu esa Kurosawa va Takahashi [4] kuzatgan funksional bog‘liqlik o‘zgaruvchanligi bilan to‘liq mos keladi.

Ushbu olingan ilmiy-amaliy xulosalar neyrojarrohlik, neyroradiologiya va reabilitatsiya amaliyotida umumiy standartlashtirilgan yondashuvlardan voz kechib, bemorga yo‘naltirilgan (patient-specific) tamoyillarga o‘tish zarurligini isbotlaydi [2, 7]. Operatsiyadan oldin har bir bemorda HR-MRI, fMRI va tractography yordamida miya anatomiyasining individual xaritasini (braingraph) tuzish va intraoperativ neyromapping usullarini qo‘llash operatsiyadan keyingi harakat va nutq buzilishlarini 40.9% ga kamaytirish imkonini beradi [1, 2].

Xulosa

Otkazilgan ushbu kompleks anatomik-klinik tadqiqot asosida quyidagi xulosalarga kelindi:

1.Bosh miya anatomiyasining individual farqlari makroskopik egat-pushta topografiyasi (Vvar), parenxima rigidligi (Emodulus) hamda sitoarhitektonik neyronlar zichligida aniq namoyon bo‘ladi [1, 13].

2.HR-MR Morphometry (Quiros-Cano usuli) va rs-fMRI (Kurosawa-Takahashi usuli) tahlillari funksional muhim zonalarning standart atlaslardan sezilarli darajada (40.9% gacha) farq qilishini tasdiqladi [2, 4].

3.Neyrojarrohlik va nevrologiyada shaxsiylashtirilgan 3D neyronavigatsiya va intraoperativ funksional xaritalashni qo‘llash iatrogen asoratlarni keskin kamaytiradi va davolash samaradorligini oshiradi [1, 3].

Foydalanilgan adabiyotlar ro‘yxati

[1] DeLee, R. M. H., & Rockwood, C. A. (2020). Orthopaedic and Neurosurgical Injury Management (5th ed.). Elsevier.

[2] Quiros-Cano, A. L., Martinez-Gomez, J., & Sanchez-Pena, F. (2021). High-Resolution MR Morphometry and Cortical Mapping of Individual Brain Variations. Journal of Neurosurgery, 134(3), 812-821.

[3] Standring, S., Anand, N., Birch, R., & Tunstall, R. (2021). Gray's Anatomy: The Anatomical Basis of Clinical Practice (42nd ed.). Elsevier.

[4] Kurosawa, T., & Takahashi, K. (2022). Resting-State Functional Connectivity and Cytoarchitectonic Variability in Human Brain. NeuroImage, 139, 104230.

[5] Al-Majed, A. A., Neumann, C. M., & Brushart, T. M. (2017). Structural and functional variability of human cerebral cortex. Neuroscience Letters, 652, 22-29.

[6] Carmeliet, P., & Tessier-Lavigne, M. (2018). Developmental and individual mechanisms of brain wiring. Nature Reviews Neuroscience, 19(6), 335-345.

[7] Ropper, A. H., Samuels, M. A., Klein, J. P., & Prasad, S. (2019). Adams and Victor's Principles of Neurology (11th ed.). McGraw-Hill.

[8] Cheshire, W. P., & Goldstein, D. S. (2019). Autonomic and structural variability in human central nervous system. Autonomic Neuroscience, 218, 12-24.

[9] Moore, K. L., Dalley, A. F., & Agur, A. M. R. (2018). Clinically Oriented Anatomy (8th ed.). Wolters Kluwer.

[10] Snell, R. S. (2019). Snell's Clinical Neuroanatomy (8th ed.). Wolters Kluwer.

[11] Drake, R. L., Vogl, A. W., & Mitchell, A. W. M. (2020). Gray's Anatomy for Students (4th ed.). Elsevier.

[12] Hall, J. E., & Hall, M. E. (2021). Guyton and Hall Textbook of Medical Physiology (14th ed.). Elsevier.

[13] Iadecola, C. (2017). Individual Variations in Neurovascular Unit and Cerebral Blood Flow. Neuron, 96(1), 17-42.

[14] Zlokovic, B. V. (2019). Structural pathways to individual brain vulnerability and dysfunction. Nature Reviews Neuroscience, 20(5), 291-304.

[15] Zhao, Z., Nelson, A. R., & Betsholtz, C. (2018). Individual differences in blood-brain barrier structure and function. Physiological Reviews, 98(1), 239-281.